



## Which is the Cause of Death? – A Case Report

Vijay Kumar Kaushik<sup>1</sup>, M I Sheikh<sup>2</sup>

**Financial Support:** None declared  
**Conflict of Interest:** None declared  
**Copy Right:** The Journal retains the copyrights of this article.

**How to cite this article:**  
Kaushik VK, Sheikh MI. Which is the Cause of Death? – A Case Report . Ntl J Community Med 2017; 8(2):98-100.

**Author's Affiliation:**  
<sup>1</sup>Tutor; <sup>2</sup>Professor & Head, Department of Forensic Medicine, SMIMER, Surat

**Correspondence:**  
Dr. Vijay Kaushik  
vijay.kaushik62@gmail.com

**Date of Submission:** 06-01-17  
**Date of Acceptance:** 13-02-17  
**Date of Publication:** 28-02-17

### ABSTRACT

Homicide is one of the most serious consequences of interpersonal relation ending in violence. In all cases, where multiple fatal homicidal injuries have been inflicted, the principle cause of death may have to be determined. But in certain cases where marked degree of violence has been used, the autopsy facts emerge themselves with each injury playing a role in causing the death. It becomes one of the prime duties of a forensic expert to find out the cause of death in such cases, especially when multiple means of homicide are involved which indicate multiplicity of the assailants. Here is a case where the victim was murdered by inflicting multiple stab wounds over the chest and abdomen and was violently strangled along with; all the injuries collectively contributed to the death in this case. Various factors and available literature are discussed here.

**Key words:** Homicide, Stab wounds, Strangulation, Asphyxia.

### INTRODUCTION

The word homicide is derived from the Latin word *homicidium*. Homo means 'man' & caedere means 'to cut, kill'.<sup>1</sup> Homicide means one human being causes death of another. Not all homicide is murder, as some killings are manslaughter, and some are lawful, such as when justified by an affirmative defense, like insanity or self defence.<sup>2</sup> Stab wound and blunt weapon injuries are the one of the commonest causes of homicidal deaths.<sup>3</sup> The method employed may be single or multiple. Cases involving multiple homicidal injuries by various methods are rare and constitute one of the most challenging jobs for a forensic expert. Furthermore, the findings are greatly obscured if there is onset of decomposition in the body. But in some cases, like deaths from actual strangulation, the compressed tissue of the ligature mark instead of obliteration, are better preserved than the putrefied skin beyond it.<sup>4</sup> In the similar manner shape of the stab wound may be better appreciated by approximating its margins and by looking at the shape of the wound over internal organs involved, if any. In cases of multiple injuries, each injury may contribute significantly to the cause of death. The incidence of homicide has been increasing at an alarming rate in India. This is probably due to the rapid-

ly increasing population with decreasing morale, high levels of unemployment and frustration in day-to-day life. Circumstantial evidence plays a major role in drawing conclusions about homicidal deaths, as in other aspects of forensic medicine.<sup>5</sup> The emphasis is laid upon the same with the help of the case described here.

### CASE HISTORY

Dead body of a male aged 45 years old was brought to the mortuary of SMIMER, Surat on 12/06/15 at 10.15 a.m. with history of homicidal death with multiple abrasions, contusion, incised and stab wound with two horizontal incomplete ligature marks encircling the neck. According to the investigating officer, the body was wrapped in cloth and thrown on side of road near railway track.

#### On postmortem examination following findings observed:

A male aged about 45 years, wt. 62 kg & 166 cm length, moderately built, well nourished and cold. Rigor mortis was present all over the body. Faint P.M. lividity was present on posterior aspect of the body. Face congested & stained with dried blood.

Tongue inside oral cavity. Clothes were soaked with blood. Multiple cuts mark present on shirt, paint & undergarments. Green nylon rope ligature material was present over neck with fixed knot.

**External injuries:**

1. Multiple abrasions over face chin & neck.
2. Five stab wounds- over front of left shoulder, left side of chest and abdomen, at lower right chest and abdomen & right thigh with medial angle acute & lateral angle comparatively blunt.
3. Two incised wounds - over left side of chest.
4. Ligature mark : 2 horizontal complete ligature mark around the neck at the level of thyroid cartilage with crescent abrasions on left side of neck with fixed knot green nylon rope ligature material.

**Internal finding**

1. Extravasations of blood over fronto-parital region with
2. Subarachnoid haemorrhage and in neck muscle with fracture of hyoid bone on right side.
3. Left side of chest 5<sup>th</sup> and 6<sup>th</sup> ribs cut & cavity contain 500 ml blood with stab wound at lower lobe of left lung through and through.
4. Abdominal cavity contain 1.5 liters partially clotted blood and two stab wounds was present through and through over right lobe of liver.

All other organs were pale.

**CAUSE OF DEATH**

After completion of autopsy it was opined that the cause of death in this case is Shock as a result of haemorrhage due to multiple stab wound in multiple organs and associated with ligature strangulation.

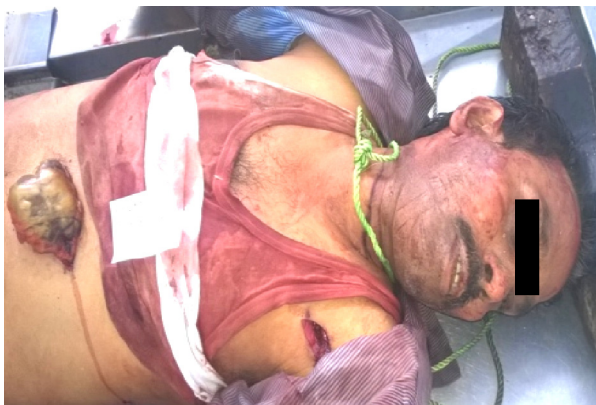

Fig 1: Injuries with ligature

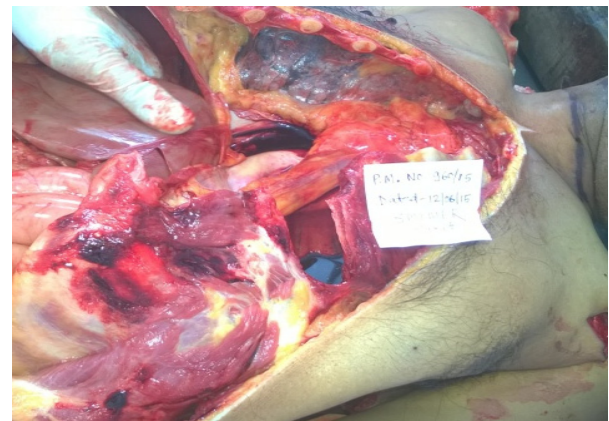

Fig 2: Injury in chest wall and cavity

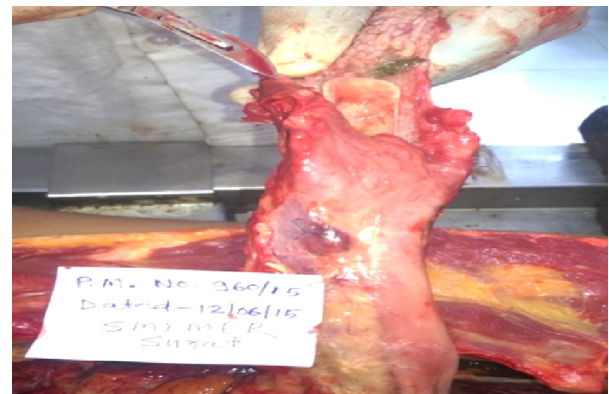

Fig 3: Fracture neck bone

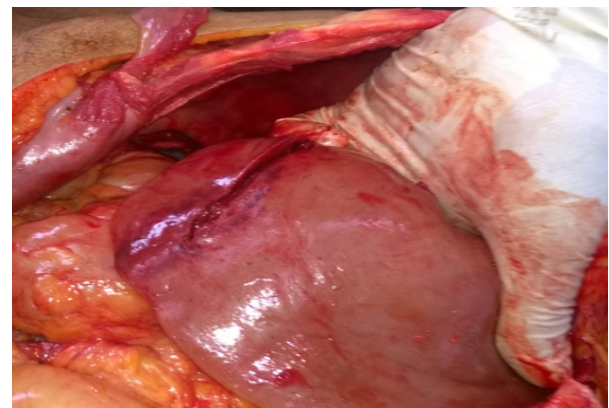


Fig 4: Injury over liver

**DISCUSSION**

The cause of death is the disease or injury responsible for starting the sequence of events, which are brief or prolonged and which produce death. Manner of death may be suicidal, homicidal and accidental or of undetermined or unexplained origin.<sup>6</sup> A number of cases have been reported all across the world where multiple methods of homicide have been used to kill a single victim. A case study from Romania indicates that a victim was killed by 3 different mechanisms of asphyxia:

smothering with the hand, manual strangulation with the other hand, and traumatic asphyxia by thoracic compression with the knees.<sup>7</sup> The autopsy findings in multiple means of homicide may help in revealing the involvement of more than one assailant that plays an important role in police investigation and trial of the case in the court. While framing the opinion on these points before the Court of Law, the medico-legal expert shall have to justify his remarks based on such findings observed during autopsy.

## CONCLUSION

It becomes one of the prime duties of a forensic expert to find out the cause of death in such cases, especially when multiple means of homicide are involved which indicate multiplicity of the assailants. Here is a case where the victim was murdered by inflicting multiple stab wounds over the chest and abdomen and was violently strangled along with; all the injuries collectively contributed to the death in this case. In such cases the opinion

as to the cause and manner of death carries utmost importance as to the nature and manner of infliction of each injury.

## REFERENCE

1. Irving, Shae. Nolo's Plain-English Law Dictionary, Ed. (2009) "homicide". Berkeley: Nolo; pp. 204-5.
2. Cornell Law University: Legal information Institute. Available at <http://www.law.cornell.edu/wex/homicide>. Accessed on December 3rd, 2014.
3. Mohanty MK, Mohanty S, Acharya S. Circumstances of crime in homicidal deaths. *Med Sci Law*. 2004 Apr; 44(2):160-4.
4. Karmakar RN. J.B. Mukherjee's Forensic medicine and toxicology. 4<sup>th</sup> ed. Kolkata: Academic Publishers; 2011: p.528.
5. Gupta A, Rani M, Mittal AK, Dikshit PC. A study of homicidal deaths in Delhi. *Med Sci Law*. 2004 Apr; 44 (2):127-32.
6. Reddy KSN. The essentials of forensic medicine and toxicology. 32<sup>nd</sup> ed. Hyderabad: Om Sai Graphics; 2013: p. 138
7. Lupascu C, Lupascu C, Beldiman D, Mechanical asphyxia by three different mechanisms. *Legal Med* 2003; 5:110 -1.