

Case Report**A CASE OF INVASIVE MICRO PAPILLARY CARCINOMA OF THE BREAST WITH LITERATURE REVIEW****Amrish N Pandya¹, Arpita Nishal², Hemali Tailor³**¹Associate Professor, ²Associate professor (IHBT), ³Assistant Professor, Department of Pathology, Government medical college and new civil hospital, Surat**Correspondence:**

Dr. Amrish N Pandya

702 /B, Amrutdhara Apts, Opp. St. Xavier's School,

Ghod Dod Road, Surat-396001

Email: dr.amrish21@yahoo.com Mobile: 9824196639

ABSTRACT

Invasive micro papillary carcinoma has been recognized as rare but distinctive variant of carcinoma in various anatomic sites, including breast, urinary bladder, lung and major salivary glands. The tumor is characterized by nested pattern of eosinophilic tumor cells arranged in a solid, morular, tubular patterns. Most often this growth pattern is mixed with conventional carcinoma or other variants. Patients have typically high-stage disease at presentation and a poor clinical outcome compared with that of patients with conventional carcinoma arising in the same organ site.

We report a case of 65 year old woman with painful lump in right breast, admitted to the surgical ward of our institute, diagnosed as invasive micro papillary carcinoma of the breast histopathologically and immunohistochemically.

Keywords: Breast, micro papillary carcinoma, invasive**INTRODUCTION**

Invasive micro papillary carcinoma of the breast has been recently described as a poorly recognized aggressive and a rare variant (<3%) of infiltrating duct carcinoma. It is definitively associated with lymphatic invasion and a high incidence of nodal metastases.^{1,2}

CASE REPORT

A 65 year old woman presented with a painful lump in the right breast since last two months. Physical examination revealed a discrete mass in central location of the right breast. A diagnosis of mammary carcinoma was made on Fine needle aspiration cytology. The patient underwent a right modified radical mastectomy with axillary dissection.

The mastectomy specimen was sent to the surgical pathology laboratory of our institute. On gross examination, the specimen measured 30cmx25cmx5cm with 27cmx12cm epidermis

and nipple. On the cut surface of the breast there was a 2.5cmx2cm ill-circumscribed mass lesion, 3 cm away from nipple, with extensive fibrosis.

Required sections from the mass, lymph nodes and margins were taken, processed and stained with H & E stain as well as underwent Immunohistochemistry procedures.

On low power microscopic examination the tumor was constituted of abundant invasive epithelial nests, small syncytial groups, cohesive tumor cell clusters surrounded by clear spaces and the stroma surrounding the clear spaces had a fine reticular to collagenous structure. The cell clusters mainly had round pattern while some of them had serrated peripheral borders. Some of the group has central lumen. There was no desmoplasia around epithelial cell nests.

On high power microscopic examination, the epithelial cells were cuboidal to columnar with variable amount of cytoplasm that ranges from finely granular to densely eosinophilic in nature

(Fig. 1). Myoepithelial cells were not seen at the periphery of cell clusters.

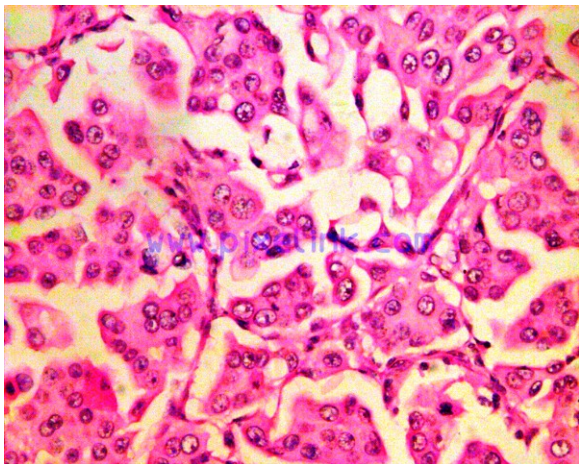


Fig. 1: Cuboidal to columnar epithelial cells with variable amounts of cytoplasm that ranges from finely granular to densely eosinophilic (H&EX400)

Histological grading and mitotic index were fairly high and pleomorphism was present. Total 8 lymph nodes were identified, 3 lymph nodes showing metastases and the remaining showed features of sinus histiocytosis.

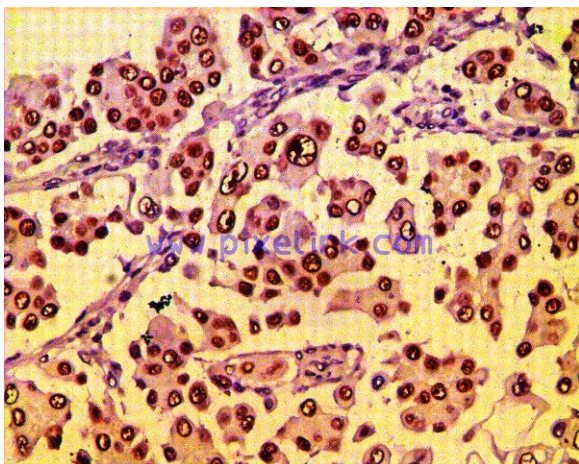


Fig. 2: Estrogen receptor positivity

Immunohistochemistry for estrogen receptor (ER) (Fig.2) and progesterone receptor (PR), c-erbB-2 was performed (fig.3). Both ER and PR immunoexpressions were positive in 70% of the tumor cells. C-erbB-2 was (+++) positive in cytoplasmic membrane of the tumor cells.

DISCUSSION

Invasive micro papillary carcinoma of the breast has been recently described as a poorly recognized aggressive and a rare variant ^{1, 2}. Invasive papillary cancers were first described by Fisher et al, who recognized several subtypes in their review of 1603 patients tumors from the National Surgical Adjuvant Breast Project (protocol 4) ³. The patterns that termed exfoliative were thought clinically as with poor prognosis. In 1993 Siriaunkgu and Tavassoli from the Armed Forces Institute of Pathology described the first series of this tumor which they called as invasive micro papillary carcinoma. They noted that this pattern is a different entity from metastatic papillary carcinoma and tubular carcinoma ⁴.

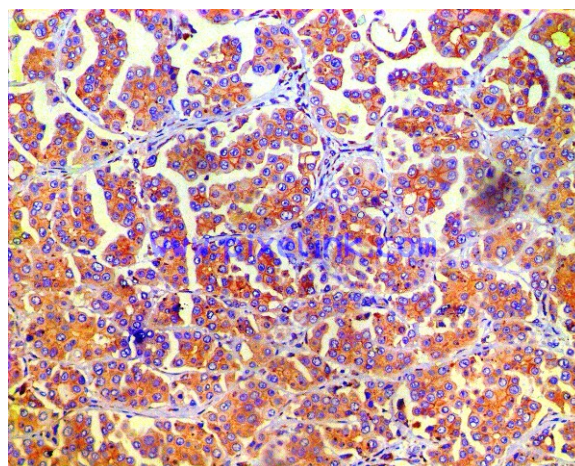


Fig. 3: HER-2/neu positivity

The tumor is best characterized by a nested pattern of eosinophilic tumor cells arranged in a solid, morular and tubular pattern. The tumor cells have intermediate to high grade nuclei and individual groups have a clear space separating them from the surrounding stroma. These spaces are not lined by endothelial cells and this is most likely shrinkage artifact. ^{4, 6}

The intraductal component that accompanies these tumors often has a micro papillary pattern in which intermediate to high grade nuclei and necrosis typically present. It has been further defined by electron microscopic analyses, which showed microvilli on the external surfaces of cell clusters. ¹

IMPC has a high % of estrogen receptor and progesterone receptor positivity (90% and 70%) and nearly doubles the expected percentage of

HER-2/neu positivity (60%).^{2, 6, 7}

ER positivity has traditionally been associated with better differentiated tumors would appear to be an exception to these general rules.

Expression of acid mucins and surface linear staining with epithelial membrane antigen antibody was also described. The clinical significance and role of prognostic markers in IMPC are not fully described. It has been shown that prognostic factors in IMPC of the breast are the grade and extensive lymphatic invasion.² Other factors such as ER and PR status, HER-2/neu protein over expression and p53 deletions have also been studied. It appears that the presence or absence of these markers in IMPC generally mimic that of the usual breast cancer in terms of predicting patient prognosis.^{2, 8, and 9} It has also been found that pure IMPC was associated with high-grade histology, metastases to regional lymph nodes, a high mitotic index and c-erbB-2 immune positivity.⁹¹⁰ In this case HER-2/neu immunexpressions was positive in 60% of the tumor cells. Survival rates were similar to those of other patients with equivalent numbers of lymph node metastases.⁹

In terms of the differential diagnosis of IMPC of the breast, other primary breast tumors, such as the rare invasive papillary carcinoma and colloid carcinoma, must be considered.

Invasive papillary carcinoma is Histologically distinguishable from invasive micro papillary by its lack of clear spaces surrounding tumor clusters, truly papillary architectures and typically low nuclear grade.⁶

The distinction from pure colloid carcinoma is especially relevant because mucin secretion is an occasional, albeit usually minor, feature of IMPC of the breast. The large extracellular mucin pools of colloid carcinoma are infrequent in IMPC.⁶

Metastatic tumors especially ovarian serous papillary adenocarcinoma, micro papillary variant of transitional cell carcinoma of the bladder must also be considered in the differential diagnosis.⁸ Both of these tumors may exactly mimic the histological appearance of primary IMPC of the breast.

A thorough and accurate clinical history and the presence of associated duct carcinoma in situ will aid in the correct diagnosis of primary IMPC of the breast. The observation of a papillary pattern in intramammary lymphatic tumor emboli or lymph node metastases should prompt a search for even a small amount of IMPC differentiation in the primary tumor.

Identification of this entity as a distinct variant of breast cancer seems prudent because of the predilection of IMPC for lymphatic invasion and lymph node spread.

REFERENCES

1. Luna-More S, Gonzalez B, Acedo C, Rodrigo I, Luna C. Invasive micropapillary carcinoma of the breast: A new special type of invasive mammary carcinoma. *Pathol Res Pract* 1994; 190:668-74.
2. Luna-More S, de los Santos F, Breton JJ, Canadas MA. Estrogen and progesterone receptors, c-erbB-2, p53, and Bcl-2 in thirty-three invasive micropapillary breast carcinoma. *Pathol Res Pract* 1996; 192:27-32.
3. Fisher ER, Costantino J, Fisher B, et al. Pathologic finding from the National Surgical Adjuvant Breast and Bowel Project Investigators. *Cancer* 1993; 71:2141-50.
4. Siriaunkgul S, Tavassoli FA. Invasive micropapillary carcinoma of the breast. *Mod Pathol* 1993; 660-62.
5. Petersen JL. Breast carcinomas with an unexpected inside-out growth pattern: rotation of polarization associated with angioinvasion. *Pathol Res Pract* 1993; 189:780-84.
6. Walsh MM, Bleiweiss IJ. Invasive micropapillary carcinoma of the breast: eighty cases of an underrecognized entity. *Hum Pathol* 2001; 32:583-9.
7. Gong Y, Sun X, Huo L, Wiley EL, Rao MS. Expression of cell adhesion molecules, CD44s and e-cadherin, and micro vessel density in invasive micropapillary carcinoma of the breast. *Histopathol* 2005; 46:24-30
8. Amin MB, Ro JY, el-Sharkawy T, et al. Micropapillary variant of transitional cell carcinoma of the urinary bladder. Histologic pattern resembling ovarian papillary serous carcinoma. *Am J Surg Pathol* 1994; 18:1224-32.
9. Paterakos M, Watkin WG, Edgerton SM, Moore DH 2nd, Thor AD. Invasive micro papillary carcinoma of the breast: a prognostic study. *Hum Pathol* 1999; 30:1459-63.
10. Pettinato G, Manivel CJ, Panico L, Sparano L, Petrella G. Invasive micropapillary carcinoma of the breast: clinicopathologic study of 62 cases of a poorly recognized variant with highly aggressive behavior. *Am J Clin Pathol* 2004; 121:857-66.