

CASE REPORT**MALIGNANT MELANOMA IN A RECTAL POLYP**Amar Shah¹, Sanjay Chaudhari², Apurva Shah³¹Assistant Professor, ²Professor, Department of Pathology, ³Assistant Professor, Department of General Surgery, Pramukhswami Medical College, Karamsad, Anand, Gujarat.**Correspondence:**

Dr. Amar Shah

Department of Pathology, Pramukhswami Medical College,
Karamsad -388 325, Anand, Gujarat

Email: amarshah44@gmail.com, Phone: 9909927725

ABSTARCT

Malignant melanoma is very rare in the rectum. Prompt diagnosis and treatment is necessary as chances of metastasis is very high. A 56 year old male patient came to surgical OPD for complaint of something coming out per rectum. Polyp was identified on per rectal examination the biopsy revealed malignant melanoma. Abdominoperineal resection was done. We reported this case as it is uncommon and also there is controversy in surgical treatment of choice.

Keywords: Malignant Melanoma, Rectal Polyp, metastasis**INTRODUCTION**

Moore was the first person to report melanoma of the anus and rectum in 1857¹. Rectal malignant melanoma accounts for 0.2%-0.3%² or all malignant melanoma cases and 0.1%-4.6% of malignant tumours of the rectum and anus^{3,4}. Thus melanoma is the third most common malignancy of the anorectal area⁵.

CASE REPORT

A 56 year old male patient came to surgical OPD for complaint of something coming out from rectum since 1 months, pain at daefecation and constipation. On general examination vitals are stable. Temp-Normal, Pulse-86/min, Respiratory rate-24/min, Blood Pressure-130/80mm/hg. Cardiovascular and respiratory system is normal. Per abdominal examination is unremarkable. CNS-consciousness, oriented. Per rectal examination reveal around 3x3 cm firm, globular, well defined pedunculated polyp arising in posterior wall of rectum. Routine haematological examinations were normal. Chest X-ray did not show evidence of metastasis.

HISTOPATHOLOGICAL EXAMINATION**Gross examination:** Received specimen of single black polypoidal mass measuring 7x2.5x1.2 cm.**Figure 1: Specimen of Black polypoidal Mass****Microscopic Examination:**

Section shows malignant cell arranged in sheets. The cells are highly pleomorphic and show

nucleomegaly, round to oval nuclei, vesicular to granular chromatin, prominent nucleoli with moderate eosinophilic cytoplasm. Melanin pigment is seen. Many multinucleated cells along with areas of haemorrhage seen.

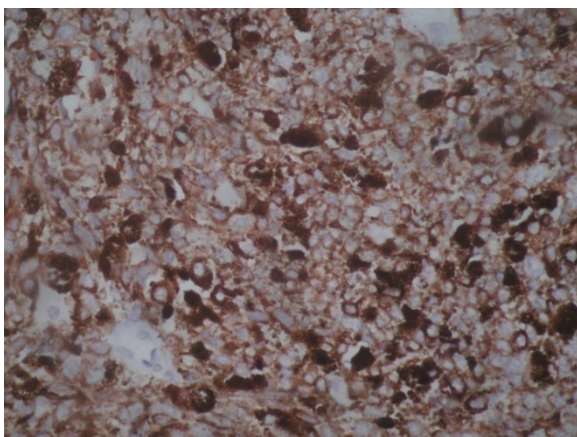
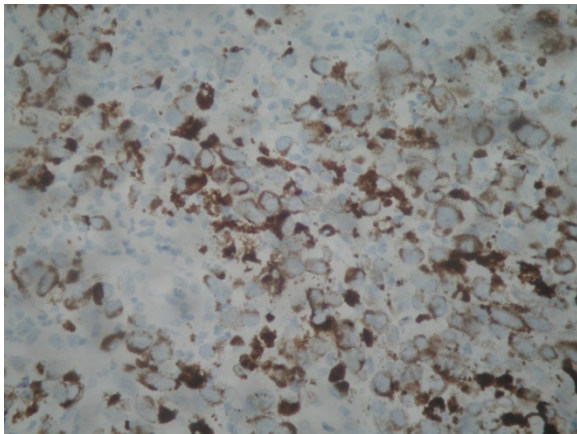
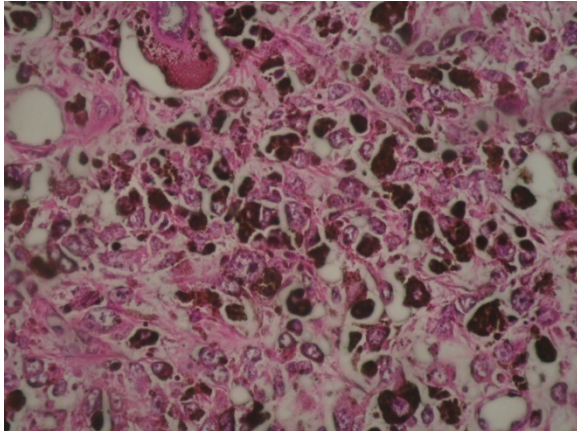


Figure 2: Immunohistochemistry-The HMB-45 and S 100 stain were positive.

DISCUSSION

Primary anorectal melanoma is an uncommon highly malignant tumour associated with an extremely poor prognosis despite aggressive

surgical treatment⁶. In a literature review by Thiebault et al., 428 patients with primary anorectal melanoma were identified from 1939 to 1996⁷. Anorectal melanoma is common in women as compared to men but in our case the affected patient was male. It accounts for 1% of all anorectal malignancies.⁸ The lesion is most often discovered in the fifth and sixth decade of life⁹.

Patient generally present with rectal bleeding and a sensation of a mass which is usually attributed to haemorrhoids or to a polyp. It is difficult to diagnosis early because of this benign symptom.¹⁰ Up to 60% of patients have been found to have metastatic disease at the time of diagnosis.¹¹ Lesions are most commonly found at the anorectum, followed by the anal canal and anal verge.¹² A diagnosis of primary rectal malignant melanoma depends primarily on the histopathological and endoscopic findings.

Macroscopically the tumors are polypoidal and pigmented while microscopically the cells are arranged in nests with characteristic immunostaining specific for melanosome protein.¹³ Malignant melanoma of the rectum has poor prognosis. The factors that may account poor prognosis include the advance nature of the disease at the time of diagnosis, ulceration, the rich vascularity of the rectal mucosa, greater risk of hematogenous metastasis and high biological aggressiveness of the tumor.¹⁴

Slingluff and cooper reported that five year survival rate was less than 10%.¹¹ Mayo clinic, however, reported five year survival rate as 22% and cure in 16% in their study.⁴ In the literature some author have found no difference in overall survival and the disease free interval between patient who had curative abdominoperineal resection and those who were treated with wide local excision^{3,15}. However, adjuvant or neo-adjuvant and immunotherapy might offer a more effective way of treating this disease^{14,16}.

CONCLUSION

Malignant melanoma of the anorectum is an uncommon condition. An early diagnosis and care within a multidisciplinary team can have an important bearing on prognosis. Histopathological and immunohistochemical examination of clinically diagnosed rectal polyp

or haemorrhoids should be done to rule out malignant melanoma. In both anal canal and primary rectal melanoma, abdominoperineal resection may provide a better local control if not longer survival.

REFERENCES

1. Moore R. Recurrent melanosis of the rectum, after previous removal from the verge of the anus, in a man aged sixty-five. *Lancet* 1857; 1:290.
1. Golden S, Babuche G, Pahlman L. Anorectal malignant melanoma in Sweden; report of 49 patients. *Dis Colon Rectum* 1990; 33:847-57.
3. Thibault C, Sagar P, Nivatvongs S, et al. Anorectal melanoma- an incurable disease? *Dis Colon Rectum* 1997; 40:661-8.
4. Weinstock M A, Epidemiology and prognosis of anorectal melanoma. *Gastroenterology* 1993; 104: 174-8.
5. Garnick M, Lokich JJ. Primary malignant melanoma of the rectum: Rationale for conservative surgical management. *J Surg Oncol* 1978;10:529-31.
6. D.Hazzan, P.Reissman, M. Halak ,M.B. Resnick, M.Loten, E.Shiloni (2001) Primary rectal malignant melanoma: report of two cases. *Springer-Verlag* 5:51-54.
7. Thibault C, Sagar P, Nivatvongs S et al (1997) Anorectal melanoma- an incurable disease ? *Dis Colon Rectum* 40: 661-668.
8. Roviello F, Cioppa T, Marrelli D, Nastri G, De Stefano A, Hako L, Pinto E: Primary anorectal melanoma: consideration on a clinical case and review of the literature. *Chir Ital* 2003, 55:575-580.
9. Prosanta kumar Bhattacharjee, Debabrata Ray, Manimala Ray, Jayati Mitra, Sagar Sadhu.
10. Anorectal amelanotic malignant melanoma. *Indian J Surg* 2003; 65:370-2.
11. Poggi SH, Madison JF, Hwu WJ, et al. Colonic melanoma, primary or regressed primary. *J Clin Gastroenterol* 2000;30:441-444.
12. Cooper PH, Mills SE, Allen MS Jr. Malignant melanoma of the anus: Report of twelve patients and analysis of 255 additional cases. *Dis Colon Rectum* 1982; 25:693-703.
13. Rijhi A, Dimosthenous K:P Primary malignant melanoma of the rectum arising against a background of rectal melanosis. *Int J Surg Pathol* 2008, 16(3):335-336.
14. Tanka S, Ohta T, Fujimoto T et al : Endoscopic mucosal resection of primary anorectal malignant melanoma: A case report *Acta Med Okayama* 2008,62(6): 421-424.
15. Pantolone D, Taruffi F, Paolucci R, et al . Malignant melanoma of the rectum. *Euro J Surg* 2000; 166:583-4.
16. Slingluff Jr CL, Vollmer RT, Seigler HF. Anorectal melanoma: Clinical characteristic and results of surgical management in 24 patients. *Surgery* 1990;107:1-9.
17. Alexander RM, Cone LA. Malignant melanoma of the rectal ampulla: Report of a case and review of the literature. *Dis Colon Rectum* 1977;20:53-5.