



# VISCERAL LEISHMANIASIS IN KERALA: AN EMERGING DISEASE

Priya Chandran<sup>1</sup>, Jayakrishnan Thavody<sup>1</sup>, Lilabi MP<sup>1</sup>, Bhaskara Rao<sup>1</sup>, Meera S Nair<sup>2</sup>, Shamin PR<sup>2</sup>

**Financial Support:** None declared

**Conflict of interest:** None declared

**Copy right:** The Journal retains the copyrights of this article. However, reproduction of this article in the part or total in any form is permissible with due acknowledgement of the source.

**Author's Affiliation:**

<sup>1</sup>Associate Professor; <sup>2</sup>Junior Resident, Department of Community Medicine, Govt. Medical College Kozhikode, Kozhikode, Kerala

**Correspondence:**

Dr. Priya Chandran  
drpriyaclt@gmail.com

**Date of Submission:** 19-07-16

**Date of Acceptance:** 19-08-16

**Date of Publication:** 31-08-16

## ABSTRACT

Leishmaniasis though endemic to certain parts of India is rare in the state of Kerala. Though cutaneous forms of the disease have been reported from a few pockets in Kerala the Visceral form is rare. We report the clinico-epidemiological profile of two cases of visceral leishmaniasis reported from Malappuram district in Kerala. The public health interventions instituted following the confirmation of diagnosis has also been mentioned.

Keywords: Leishmaniasis, Kerala, Visceral

## INTRODUCTION

Leishmaniasis is caused by parasites of the genus *Leishmania* and transmitted to man by the bite of female phlebotomus sandflies. Leishmaniasis in humans ranges from visceral leishmaniasis (VL) to cutaneous, mucocutaneous, zoonotic cutaneous and post kala-azhar dermal leishmaniasis (PKDL). The visceral form of the disease is still endemic in India in the states of Bihar, West Bengal, Jharkhand and Uttar Pradesh,<sup>1</sup> The disease is rare in the state of Kerala with few isolated cases being reported in the last decade.<sup>2,3</sup> This article describes the clinical and epidemiological features of two cases of VL from Malappuram district of Kerala which were diagnosed recently in our institution.

## OBJECTIVE:

Objectives of the report was to study the clinico-epidemiological profile of two Visceral leishmaniasis cases recently reported from Malappuram district

## METHODS

Case details of the two VL patients were collected by interviewing the patients and detailed clinical examination done during their hospital stay. Diagnosis was established by histopathological examination. Epidemiological investigation including entomological survey was conducted in and around the residences of the patients.

## RESULTS

Both of the patients were residents of Malappuram district in Kerala. They presented with prolonged fever, weight loss, hepato-splenomegaly and pancytopenia. The case details of the patients are given below.

### Case A

The patient was a 50 year old, unmarried tribal male presenting with fever of 20 days duration, loss of appetite and loss of weight. He was treated at the peripheral hospital and referred to our institution in January 2015, as the symptoms were not

relieved. On examination he had pallor, hepatosplenomegaly and bilateral pedal oedema. Investigations done revealed Hemoglobin- 6.5 g/dl, WBC count-3200 cells/mcL, Platelet count-57000 /mcL ESR- 120 mm/hr, Total protein/serum albumin- 6.2/ 2 g/dl, HIV- negative, USG abdomen - Splenomegaly. Bone marrow aspiration cytology revealed Leishman Donovan bodies in macrophages. He was treated with amphotericin B infusion for 10days, and recovered.

**Epidemiological investigation :** Epidemiological survey of his house and surroundings were done after his discharge from the hospital. The patient was residing with his sister in a tribal colony at Nilambur - Malappuram district of Kerala. The colony consisted of 5 closely clustered kutcha mud plastered houses with thatched roofs. The walls and floors had cracks and crevices favourable for harbouring insects. The residents were rearing goats and poultry in a small shed adjacent to the house. Entomological survey of the residences was done during dusk and flies were collected ( from indoor and outdoor ) by the entomologist and identified as Sandflies of the Species *Phlebotomus argentepes*

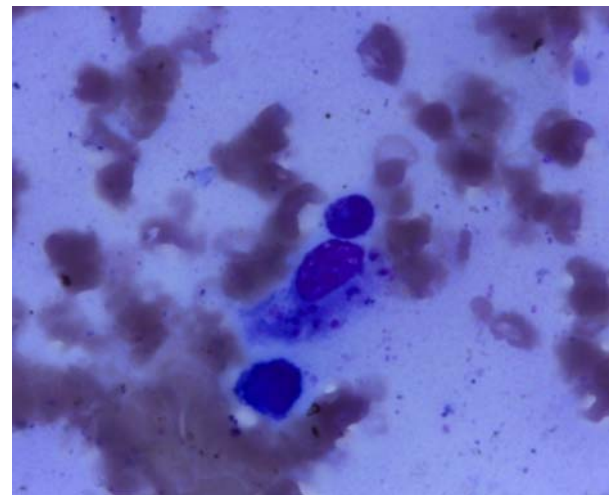
### Case B

The patient was a 45 year old, married male presenting with fever of 4 months duration, generalized lymphadenopathy, loss of appetite and loss of weight. He was treated at the peripheral hospital and referred to our institution in February 2015, suspecting lymphoma. Clinical examination revealed pallor, hepatosplenomegaly and generalized lymphadenopathy. Investigations done showed that Hemoglobin- 5.5g/dl, WBC count-3800 cells/mcL Platelet count-2.07 lakhs/mcL, ESR- 150 mm/hr, Total protein/serum albumin- 8.4/ 2.3 g/dl, HIV- negative, USG abdomen - Splenomegaly. Fine needle aspiration cytology of lymph nodes showed numerous LD bodies in macrophages. Bone marrow aspiration cytology was done for confirmation and Leishman Donovan bodies were identified in macrophages. He was treated with amphotericin B infusion for 10days following which he recovered.

**Epidemiological investigation :** Epidemiological survey of his house and surroundings was done . The patient was residing with wife and two daughters in a make shift tent as his house was under construction. The surroundings were damp and had a lot of rank vegetation. Piles of firewood and construction of the house in progress all were favourable for breeding of sandflies. Entomological survey was done at dusk and flies collected (both from indoors and outdoors) from the site were identified as *Phlebotomus argentepes*.



**Fig 1 . Immunochromatographic antigen detection rK39 test positive**



**Fig 2 . Bone marrow aspirate showing LD bodies in macrophage**

### Epidemiological survey

Two patients admitted to our institution were diagnosed with Visceral Leishmaniasis. Even though both of them were from the same district, the residences of these patients were 20 Km apart. Both gave no history of travel outside the state during the past one year. Case A gave a history of travel to Mysore, Karnataka state three years back while he was employed as a mahout there . Case B did not give any history of travel outside the district. No epidemiological link could be identified between the two cases.

The family members of both cases were tested with the rK 39 antigen based immune-

chromatographic field testing kit to identify presence of antibodies in them signifying recent infection. All family members tested negative but both the cases tested positive with the kit.

A pineapple farm 500m away from Case Bs residence was visited to identify any source of infection. The farm employed migrant labourers from Jharkand. The District health authority conducted a screening camp for the migrant workers following recommendations of the investigation team. Of the 18 workers in the farm two had fever at the time of screening. rK39 test was negative for all workers. The work force at the pineapple farm was not a permanent one – new workers were recruited continuously as old workers left.

The district health authorities were advised by the team to employ vector control measures in and around the house and a distance of 500m around the residences. Two rounds of Indoor residual spraying with the synthetic pyrethroid, cyfluthrin was done in April and May 2015 . Spraying was also done for 500 m around both the houses .

A follow up visit to the same areas was done after one month with a team from National Centre for Disease Control (NCDC) – Kozhikode . Both the patients were healthy and had gained weight and appetite. Vector survey was also done by Entomologist from NCDC. Sandflies were isolated from the environment around both houses but not from inside the house. Insecticide spraying repeated once more with synthetic pyrethroid.

Continuous surveillance didn't yield any further cases from the district even after one year.

## DISCUSSION

Cases of visceral Leishmaniasis are rare in Kerala even though indigenous cases of cutaneous Leishmaniasis have been reported from Nilambur<sup>4</sup> in Malappuram district and Trivandrum<sup>3</sup>. In 2003, two indigenous cases of Visceral Leishmaniasis were reported from Thrissur district in the state <sup>2</sup>. This is the first time that visceral Leishmaniasis has been reported from Malapuram district. The absence of travel history in both our cases rules out the possibility of imported infection. The possibility of transmission from migrant workers in the pineapple plantation cannot be ruled out. But in the absence of a positive rKT test it becomes difficult to conclude. Earlier studies have confirmed an indigenous focus of CL in Nilambur area of

Malapuram district <sup>4</sup> and tribal areas of Trivandrum district in the state.<sup>3</sup> Case reports are available from Thrissur district wherein importation from middle east was considered but two patients gave no history of travel outside the state<sup>5</sup>.

Leishmaniasis presents in varied forms so diagnosis becomes difficult unless a high index of suspicion is maintained in non endemic areas. Many cases may go undetected and undiagnosed<sup>6</sup>. Leishmaniasis was not endemic to Kerala but identification of indigenous foci of Leishmaniasis recently has changed the status. The migration of people from endemic areas for employment pose risk to the non immune home population.

Case reporting is passive and notifications are usually made from tertiary centres from where the patients are usually diagnosed. A high index of suspicion in cases reporting with fever and hepatosplenomegaly from areas where leishmaniasis has been reported is the only means of ensuring early diagnosis. Continuous surveillance for both cutaneous and visceral forms of the disease and notification of the disease is essential for the health department to institute control measures in order to contain spread.

**Acknowledgements:** We acknowledge the help extended by the District Surveillance Officer, Medical officer of Community Health centre, Malappuram District and Dr. Reghu Entomologist NCDC -Kozhikode for his valuable comments.

## REFERENCES

1. Bora D Epidemiology of visceral leishmaniasis in India. Natl Med J India. 1999 Mar-Apr;12(2):62-8.
2. Kesavan A, Parvathy VK, Thomas S, Sudha SP (2003). Indigenous visceral leishmaniasis: two cases from Kerala. Indian Pediatrics 40:373-374.
3. Simi SM, Anish TS, Jyothi R, Vijayakumar K, Philip RR et al (2010). Searching for cutaneous leishmaniasis in tribals from Kerala, India. Glob Infect Dis.2(2):95-100.
4. D Bora, AK Khera, Veena Mittal, SM Kaul, RS Sharma. New focus of cutaneous leishmaniasis in India : Preliminary report .Indian Journal of Dermatology, venerology and leprology 1996 Volume : 62 Issue : 1 Page : 19-21
5. S Criton, K Devi, PK Sreedevi, PU Ashokan, Profile of Leishmaniasis in Central Kerala. Indian Journal of Dermatology 1997:42 (2)
6. Control of Leishmaniasis , WHC , Technical Report series 793, 1990